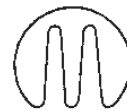

HYALURONIC ACID IMPLANT IN THE LABIAL AND PERIORAL REGION

Piero Notarrigo

HYALURONIC ACID IMPLANT IN THE LABIAL AND PERIORAL REGION



EDIZIONI MARTINA

Translated by **Margherita Notarrigo**

Copyright © 2015 Edizioni Martina s.r.l.
e-mail: info@edizionimartina.com www.edizionimartina.com
ISBN 978-88-7572-150-3

*All rights reserved. Without the written authorization of the Authors
and the Publisher, no part of the book may be copied or sent in any form
and by any means electronic or otherwise, photocopies,
tape recordings or storage included.*

Printed by Fotoincisa BICO, Bologna, Italy (September 2016)

Index

Preface I	IX
<i>(Prof. Edoardo Raposio)</i>	
Preface II	XI
<i>(Prof. Angelo Putignano)</i>	
Acknowledgments	XII
Introduction	XIII

1

BASIC KNOWLEDGE

OUTLINE OF THE ANATOMY AND HISTOLOGY OF THE LABIAL AND PERILABIAL REGION

1.1 Young lips	2
1.2 Aesthetic proportions in young lips	3
1.3 Ageing of labial and perioral region	3
1.4 Vascularisation of the lower third of the face.....	4
1.5 Perilabial areas prone to bruising after injection of material	4
1.6 Injection areas and vascularisation	5
1.7 Lip histology.....	6
1.8 Hyaluronic acid injection areas	6
1.9 What am I going to inject? Biocompatibility and chemical-physical characteristics of HA	7

2

THE PRACTICE

THE REDUCTION OF NASOLABIAL FOLDS AND MARIONETTE LINES

2.1 General considerations	8
2.2 Prepare the patient for the treatment: facial cleansing, application of topical anaesthetic, disinfection	9
2.3 Treatment of Marionette lines, injection techniques, critical issues	11
2.4 Treatment of the nasolabial fold, injection techniques, critical issues	13
2.5 Final result	20

Index

3	LIP INCREASE IN TONE AND VOLUME	
3.1	General considerations	21
3.2	Prepare the patient for the treatment: facial cleansing, application of topical anaesthetic, disinfection	22
3.3	Treatment execution – injective techniques, critical issues	24
3.4	“Before and after”	35
4	NASOLABIAL FOLDS REDUCTION, MARIONETTE LINE REDUCTION AND INCREASE IN THE VOLUME OF THE LIPS	
4.1	General considerations.....	37
4.2	Prepare the patient for the treatment: cleansing, application of topical anaesthetic, disinfection.....	38
4.3	Reduction of Marionette lines – injection techniques, critical issues	39
4.4	Nasolabial folds reduction – injection techniques, critical issues	40
4.5	Increase in lip volume – injection techniques, critical issues	45
4.6	“Before and after”	56
5	INCREASE IN VOLUME OF THE VERMILLION AND THE TUBERCLE IN A PATIENT WITH ASYMMETRIC UPPER LIP LINER TATTOO	
5.1	General considerations	57
5.2	Prepare the patient for the treatment: cleansing, application of topical anaesthetic, disinfection.....	57
5.3	Increase in volume of the Vermillion and the tubercle – injection techniques, critical issues	58
5.4	“Final result”	62



Index

6 SIDE EFFECTS AND COMPLICATIONS

6.1 a) Side effects	
6.1.1 Reddening-oedema	63
6.1.2 Bruise	65
6.1.3 Pain, itching	65
6.1.4 Local hardening	66
6.1.5 Post-treatment asymmetries	66
6.1.6 Tyndall effect	67
6.2 b) Complications	
6.2.1 Infection	67
6.2.2 Ischaemic necrosis	67

7 THE ROAD MAP

7.1 Which product should I use?	68
7.2 How much should I charge?	68
7.3 Informed Consent	70
7.4 Case of emergency	73
Bibliography	74



Preface I

I am pleased to introduce this latest editorial work by my friend and colleague Piero Notarrigo. For several years the author has been teaching in the Master's Program of Aesthetic Medicine, which I direct, at the University of Parma. He scores resounding success among the students, thanks to his linear, detailed, practical and interactive lessons. Many Aesthetic MD, beginners or not, will I am sure make the most of his sound experience in this specific field, the filler practice, which is widespread. The text is enriched by a complete iconography, which guides the reader step by step in the correct injective practice. The author gives some precious practical advice on how to manage these specific clinical cases. I sincerely congratulate Piero Notarrigo, wishing this book the success it deserves.

Prof. Edoardo Raposio

Director of Plastic Surgery and the school
of specialization in Plastic,
Reconstructive and Aesthetic Surgery,
University of Parma.



Preface II


When the editor Martina sent me the draft of this book, I immediately thought: perhaps I am not the most appropriate person to write this preface. Then, I read the book thoroughly and I was struck by the Doctor's mild manners and his detailed indications for the treatment. At a time when every dental practice is ruled by the "over treatment", this book maintains a conservative approach while responding to those who want to familiarise with this discipline.

Never forget the first rule of Medicine: *primum non nocere* (First, do no harm). I wish you good reading.

Prof. Angelo Putignano

Full professor of Restorative Dentistry
President of the degree course in
Dental hygiene
Marche Polytechnic University

Scientific editor of the magazine
"Cosmetic Dentistry"



I would like to express my personal thanks to Martina publishers, to my friends Alfredo and Vincenzo, who supported, helped and encouraged me to complete this project. I want to thank them for the patience they showed respecting my work patterns which I sometimes, had to slow down due to my work commitments. Immediately after the publisher Martina, I would like to thank Raffaella of Zanini Graphics, She has constantly been present , diligent, and very competent in effecting the layout of the texts and photos.

Warm thanks go to my models, Eva, Lola, Vanessa and Francesca who enthusiastically accepted to undergo the treatments I proposed, later appearing as the main characters in this book. Finally, a special thank to my family, my wife Cristina and my daughter Margherita, who patiently dealt with me being absent at times, the weekends spent working on my computer, the moments in which, immersed in my work, I was not very present.

My final thanks go to the reader who has demonstrated his/her trust by reading my book and I sincerely hope it was worth it. I am always available to receive any suggestions, disapproval, advice by e-mail info@pieronotarrigo.it.

Acknowledgments

Dr. Piero Notarrigo



Introduction

The book, which I would define as an illustrated volume or handbook, has its origin in a practical course I held in my Medical Office. During this course I presented some clinical cases through a didactic itinerary designed to progressively illustrate the related complications. The book is rich in images and represents a sort of flow-chart of the different moments with the patient: the medical examination, the shared decision on what kind of treatment to undertake, the injection techniques employed, and the final result. In order to keep to this outline, the opening chapters, concerning the anatomy and vascularisation of the lips and perioral area are also structured with the use of real images of the patients' faces. This illustrated volume has a marked practical purpose, indeed, I reported references to other volumes for any possible detailed study regarding the chemical-physical characteristics of hyaluronic acid and international scientific literature's review. My practical experience goes back to the end of the 1990s, when hyaluronic acid began to be employed for aesthetic purposes, and was combined with my teaching experience within the Masters Course of Aesthetic Medicine at the University of Parma and the Republic of San Marino (Italy). In this illustrated volume I wanted to include all the "fundamentals", the basic techniques I learned, in order to help the beginner who aims to carefully and correctly approach step by step the injection of hyaluronic acid into the lips and perioral area. The more experienced colleague may find it constructive to compare his approach when interacting with the patient to that recommended in this book as a sort of "peer review". The basic techniques I have illustrated, are applied first in simple cases, such as the reduction of the nasolabial folds and "Marionette lines", in order to gradually familiarise with the consistency of the product, the pressure to apply on the syringe plunger, the quantity of product to employ, the resistance encountered while penetrating the needle and how to manage the patient's reaction. At a later stage, you can deal with an increase in fullness and tone of the lips, remembering to use a lighter product to make any mistakes look less pronounced. Only then, following a regular learning curve, can you treat an increase in the volume of the lip respecting and highlighting the critical points, such as the Vermilion border, a well-proportioned increase of the Vermilion, the Cupid's Bow, the tubercle. This will be a long and gradual learning process but, in the end, you will be rewarded with the satisfaction you deserve, which is represented by the patient's enthusiastic expression and compliments!

Dr. Piero Notarrigo